

H. Sharifian MD¹
L. Aghaghazvini MD²
M. Aghaghazvini MD³
H. Mazaher MD¹
Sh. Sharif Kashany MD¹

1. Assistant Professor, Department of Radiology, Amir-Aalam Hospital, Tehran University of Medical Science, Tehran, Iran.

2. Department of Radiology, Amir-Aalam Hospital, Tehran University of Medical Science, Tehran, Iran.

3. Assistant Professor, Ear and Nose and Throat Surgeon, Iran University of Medical Science, Tehran, Iran.

Corresponding Author:

Leila Aghaghazvini

Address: Department of Radiology, Amir-Aalam Hospital, Saadi St. Tehran, Iran.

Tel: +9821-66704998

Fax: +9821-66704805

Email: la_ghazvini@yahoo.com

Received May 12, 2007;

Accepted after revision August 26, 2007.

Iran. J. Radiol. Summer 2007;4(4):217-21

The Diagnostic Value of Computed Tomography in Determining Invasion to Carotid Arteries by Head and Neck Malignant Tumors

Background/Objective: Awareness of invasion to the walls of the carotid arteries by malignant tumors, either tumoral mass or metastatic lymph nodes, is of great clinical importance before surgery and can change the management strategy. This study was conducted to assess the diagnostic value of computed tomography (CT) in determining invasion to carotid artery (CA) by oromaxillofacial and neck malignant tumors.

Patients and Methods: CT with contrast was performed in 40 patients who has had oromaxillofacial and neck malignant tumors before surgical intervention. Abnormal CT findings in our patients were categorized into 6 types: I) tumor encasement of carotid arteries ≥ 270 degrees; II) tumor encasement of carotid arteries ≥ 180 degrees; III) compression and deformation of CA; IV) displacement of CA; V) ill-defined CA wall; and VI) the segmental deletion of fat or fascial planes between tumor and CA. The CT appearances of all tumors were prospectively compared with surgical findings.

Results: Abnormal CT findings in our patients included 6 with form I; 17 with type II; 2 with type III; 8 with type IV; 7 with type V; and 33 with type VI. Surgical findings showed that the tumors invaded CA vessels in 13 of 40 patients. The sensitivity, specificity, accuracy and positive and negative likelihood ratio values with 95% confidence interval for type I were 0.31, 0.93, 0.7, 4.15 and 1.3; for type II were 0.62, 0.67, 0.65, 1.8 and 1.7; for type III were 0, 0.93, 0, 63, 0 and 0.93; for type IV were 0.07, 0.74, 0.53, 0.3 and 0.8; for type V were 0.39, 0.93, 0.69, 5.2 and 1.6; and for type VI were 1, 0.26, 0.50 and 1.35, respectively.

Conclusion: Though many CT findings are of value in determining of CA invasion by head and neck tumors, our study demonstrated that encasement ≥ 270 degree (type I), ill-defined wall of the artery (type V) and segmental deletion of fat or fascial planes between tumor and CA (type VI) are valuable in determining CA invasion by tumors. However, CT is not a definite way for the diagnosis of CA involvement by malignant tumoral lesions.

Keywords: computed tomography, carotid artery, head and neck, malignant tumors

Introduction

Carotid artery is an important structure in the neck which communicates with intracranial structures and supplies the major part of brain blood circulation. The upper neck is one of the most common sites of malignant lesions and their regional metastatic lymph nodes which could invade adjacent structures such as carotid arteries.¹⁻⁵

Malignant invasion of carotid arteries can affect the prognosis and management of patients. Invasion of carotid arteries by tumors could change the therapy planning; sometimes patients with carotid artery invasion may be found non-operable and thus, it is important to determine it preoperatively. There is no cure for head and neck cancers invading carotid artery except for complete resection of tumor. However, head and neck surgeons hesitate to resect the carotid artery because of the postoperative risk of neurologic sequela. Therefore, it is important

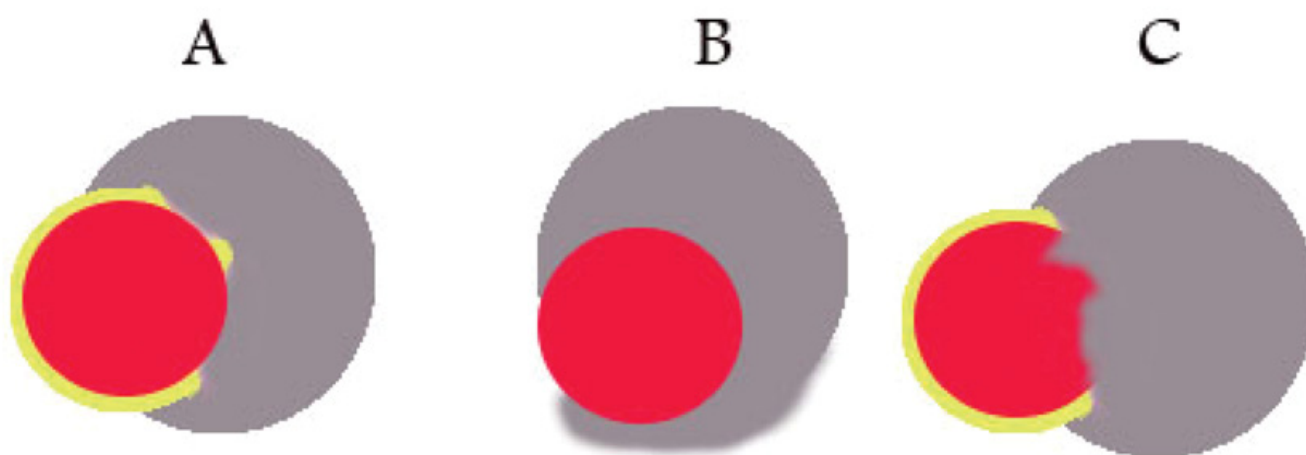


Fig. 1. Schematic views of carotid invasions.

A. form II, **B.** form I, **C.** form V. In each type, the segmental deletion of fat plane can be seen.

Red: Artery, Gray: Tumoral mass, Yellow: Fat plane.

to identify operable patients. For this reason non-invasive imaging modalities rather than clinical evaluation is necessary in predicting carotid artery invasion.³

Ultrasonography, computed tomography (CT) and magnetic resonance imaging findings of invasion of the carotid artery by malignant processes have been extensively described.^{1,4-9}

As CT is usually the first and the most-frequently used non-invasive method for detection of the pathologic location, metastatic lymph nodes and tumoral extension and sometimes staging of head and neck malignant tumors. So far, many authors have evaluated carotid invasion by different methods, however few studies considered multiple criteria for it according CT findings.^{8,9} The objective of this study was to explain the CT appearances and its value in determining invasion to carotid artery by head and neck malignant tumors.

Patients and Methods

This cross-sectional study was performed on 40 patients with malignant head and neck tumors—primary or metastatic—adjacent to carotid arteries, who were referred to our radiology department by their clinicians for standard contrast-enhanced CT of their neck for staging of the disease. All selected patients underwent surgical neck dissection and tumoral resection with complete records of the operation and pathology reports between 2005 and 2006. All

patients in whom the operative procedure was not clear were excluded from the study.

The CT scanner was a third generation machine (Toshiba XVID, China). All patients were placed in supine position for axial sections with 5-mm thick slice and 7-mm interval from skull base to thoracic inlet. CT was performed after an intravenous bolus injection of 100 mL of nonionic contrast medium; images were viewed in soft tissue window.

Carotid artery invasion were categorized into the following six forms (Fig. 1):

- Type I; tumoral encasement ≥ 270 degrees of carotid arteries circumference
- Type II; tumoral encasement > 180 degrees of carotid arteries circumference
- Type III; compression and deformation of carotid arteries
- Type IV; displacement of carotid arteries
- Type V; ill-defined wall of carotid arteries
- Type VI; segmental deletion of fat or fascial plane between carotid arteries and tumoral masses

CT results were reported by two board-certified experienced radiologists independently. The level of agreement between their results was compared by Kappa statistics.

Findings were recorded by check list and were analyzed in regard with sensitivity (SEN), specificity (SPE), positive predictive value (PPV), negative predictive value (NPV), accuracy (ACC) and positive and negative likelihood ratios (LR+ and LR-) using the intra-operative observations of two experienced ENT

Table 1. Diagnostic value of carotid invasion according to CT manifestations

Tumor State	Actually Present		Actually Absent		SEN [95%CI]	SPE [95%CI]	LR+ [95%CI]	LR- [95%CI]	PPV [95%CI]	NPV [95%CI]	ACC. [95%CI]
	Positive in CT	Negative in CT	Positive in CT	Negative in CT							
Form I>270	4	9	2	25	0.31 [0.09-0.61]	0.93 [0.76-0.99]	4.15 [0.9-19.8]	1.3 [0.9-2]	0.67 [0.22-0.96]	0.73 [0.56-0.87]	0.7 [0.03-0.57]
Form II>180	8	5	9	18	0.62 [0.32-0.86]	0.67 [0.46-0.83]	1.8 [0.9-3.7]	1.7 [0.8-3.6]	0.47 [0.23-0.72]	0.78 [0.56-0.93]	0.65 [0.04-0.56]
Form IIIcompression	0	13	2	25	0	0.93 [0.76-0.99]	0	0.93 [0.83-1]	0	0.66 [0.49-0.80]	0.63 [0.22-0.03]
Form IVdisplacement	1	12	7	20	0.07 [0.001-0.36]	0.74 [0.54-0.89]	0.3 [0.04-2.2]	0.8 [0.6-1.1]	0.13 [0.0030.52]	0.63 [0.4-0.7]	0.53 [0.44-0.03]
Form VIII defined wall	5	8	2	25	0.38 [0.14-0.69]	0.93 [0.73-0.99]	5.2 [1.2-23.3]	1.6 [0.9-2.34]	0.71 [0.29-0.96]	0.76 [0.57-0.88]	0.69 [0.05-0.66]
Form VI Fat deletion	13	0	20	7	1 [0.75-1]	0.26 [0.11-0.46]	1.35 [1.08-1.68]	-	0.39 [0.23-0.58]	1 [0.6-1]	0.5 [0.04-0.33]

SEN, SPE, PPV, NPV, ACC, LR+, LR- and CI: sensivity, specificity, positive predictive value, negative predictive value, accuracy, positive and negative likelihood ratio and confidence interval, respectively. All forms are described in methodology section.

specialists as the gold-standard of diagnosis.

Results

Of 40 patients studied, 27 were male and 13 were female. The mean±SD age of patients was 56.9±13.6 (range: 23–80) years.

The primary sites of head and neck tumors were larynx in 13 patients, parotid in 10 patients, thyroid in six, pharynx in five, tongue in four, and two metastatic lesions from the mandible osteosarcoma and orbital rhabdomyosarcoma. Primary tumoral masses that invaded carotid arteries were detected in 16 patients; other patients were involved by metastatic lymph nodes. From 24 patients with metastatic lymph nodes, 16 lesions consisted of central necrosis and 10 had conglomerated appearances—the main criteria for malignant lymph node appeared in CT.

At the operation, 13 patients were found to have lesions which invaded either common or internal carotid arteries.

The abnormal CT manifestations of patients with carotid arteries involvement were determined and each patient had one or more of the different forms of invasion:

Type I was observed in six tumors; form II in 17; form III in two; form IV in eight; form V in seven tumors and form VI in 33 tumors.

The kappa statistics for level of agreement between two radiologists in forms I, III and IV was 1; and for forms II, V and VI were 0.85, 0.8, and 0.84, respectively which reflected an excellent level of agreement for all forms.

Table 1 shows the test specifications of CT results compared to intraoperative findings. Among 13 lesions invaded carotid arteries observed during operation, four had type I on CT, eight had type II on CT, one had type IV, five had type V and 13 had type VI on CT. None had type III. Of those 13 lesions invaded carotid arteries, four presented with a combination of forms I, V and VI on CT; one had a combination of forms II, V and VI on CT; three presented with combination of forms II and VI; and one lesion had a combination of forms IV and VI on CT. SEN, SPE, PPV, NPV and ACC for combination of forms I, V and VI were 0.31, 0.96, 0.80, 0.74 and 0.75, respectively, with LR+ of 8.3 and LR- of 1.3 (Figs. 2 and 3).

Discussion

The important role of CT in evaluation of head and neck malignant lesions and their metastatic lymph nodes has been generally recognized. Definition of the relation of neoplasm and carotid arteries is crucial in patient management and prognosis preoperatively because it should be determined whether the carotid

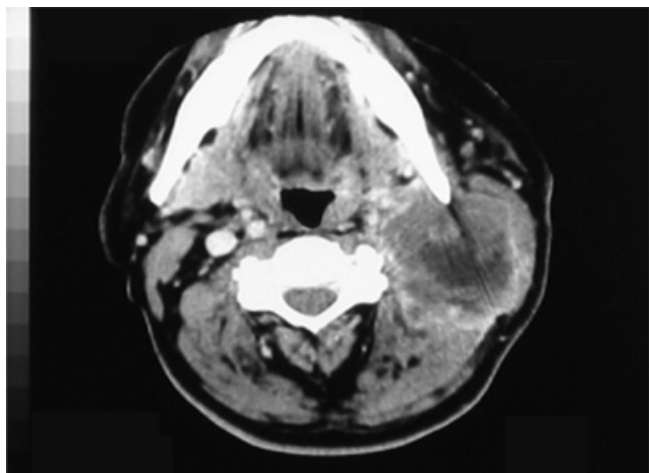


Fig. 2. A 77-year-old male with metastatic lymph node of larynx SCC with central necrosis and conglomerated appearance that is adherent to internal carotid artery with type I, V and VI CT manifestations.

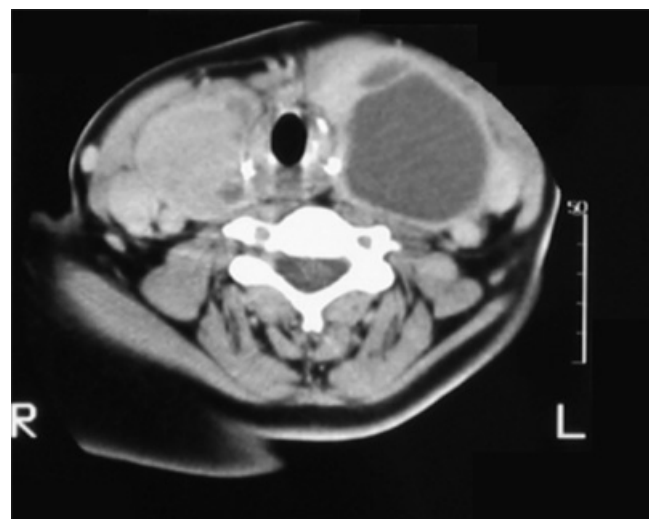


Fig. 3. A 77-year-old female with thyroid papillary cell carcinoma with type IV and VI CT manifestations.

artery should be resected or not whenever it lies adjacent to tumors. On the other hand, it is important to determine if it is possible to resect carotid artery or not, because it is a major artery feeding the brain and its resection can lead to irreversible brain damage. Diagnostic values of invasive methods such as angiography and balloon test is recognized in previous studies. Different studies have been demonstrated different accuracy of various non-invasive modalities as US, CT and MRI in carotid artery invasion.¹⁻⁹

In our study, SEN, SPE and ACC in type I invasion (encasement $\geq 270^\circ$) were 0.31, 0.93 and 0.70, respectively, with a LR+ of 4.15 and and LR- of 1.3. Saravan studied 25 patients with head and neck cancers and reported SEN, SPE and ACC of 0.75, 1 and 0.96, respectively, for encasement of the carotid arteries $>270^\circ$.³ In both studies, SPE was more than SEN. The

difference observed between these studies might be attributed to the larger sample size used in our study—40 patients in our study *vs* 25 in Saravan's study.

In our study, SEN, SPE and ACC in type II (encasement $>180^\circ$) were 0.62, 0.67, 0.65, respectively, with a LR+ of 1.8 and a LR- of 1.7. Qiang studied 43 patients with oromaxillary malignancy; only 11 of them were found to have carotid invasions during operative surgery which yielded SEN, SPE and ACC of 0.19, 1, 0.50, respectively for encasement of the carotid arteries $>180^\circ$.⁹ Differences between the two studies could be due to few number of patients with carotid artery invasion according to the operative observations in Qiang study (11 *vs* 13 in our study), ethnicity of participants, *etc.*

In our study, the SEN, SPE and ACC in type III, were 0, 0.92, and 0.62, respectively with a LR+ of 0 and a LR- of 0.93. According to Qiang's study, SEN, SPE and ACC in this type were 0.34, 1 and 0.84, respectively.⁹ In both studies, the SPE was more than the SEN.

In our study, the SEN, SPE and ACC in type IV were 0.7, 0.74 and 0.52, respectively with a LR+ of 0.3 and a LR- of 0.8; in Qiang's study, those were 0.36, 0.54 and 0.61, respectively.⁹ In our study, we had more SPE (0.74) and less SEN. Our difference with Qiang's study in the latter forms, could be due to few intraoperative observations of patients with carotid artery invasion (13 in our study *vs* 11 in Qiang's study), ethnicity of participants, *etc.*⁹

In our study, SEN, SPE and ACC in type V were 0.39, 0.93 and 0.69, respectively. These results were compatible with those of Qiang's study. We had a LR+ of 5.2 and a LR- of 1.6.

The SEN, SPE and ACC in type VI were 1, 0.26 and 0.50, respectively with a LR+ of 1.35 in our study; in Qiang's study, those values were 0.91, 0.82 and 0.84, respectively.⁹ In our study, this criteria was more sensitive and less specific. The great difference observed between our and Qiang's study in type VI invasion could be attributed to the obvious less number of lesions with type VI CT reported by Qiang (16 in Qiang's study *vs* 33 in our study). However, other contributing factors like patients selections may also be important.

Qiang showed that the signs of compression and de-

formation of common or internal carotid arteries, ill-defined carotid arteries wall and deletion of fat or fascial planes between a tumoral mass and common or internal carotid arteries may be valuable for the diagnosis.⁹ We found that encasement $\geq 270^\circ$, ill-defined wall of arteries and deletion of fat or fascial planes between a tumoral mass and the common or internal carotid arteries may be valuable diagnostic clues. As noted before, the above-mentioned factors could interpret the differences between the two studies. Our study showed that a combination of two or more types was more accurate than any of them alone. We found SEN, SPE, PPV and ACC of 0.31, 0.96, 0.80 and 0.75, respectively with a LR+ of 8.3 and a LR- of 1.3 for combinations of the types I, V and VI.

Finally, it should be noted that although many criteria could be considered in carotid arteries invasion in CT, the definite diagnosis in suspicious conditions remains difficult and additional modalities is necessary to confirm the diagnosis.

References

1. Cummings Ch, Fredrickson J, Lee A, Krause Ch. *Otolaryngology Head and neck surgery*, 4th ed. UAS; Mosby: 2005. p. 68-72.
2. Haaga Jo. *CT and MRI imaging of whole body*. 4th ed. Ohio; Mosby: 2003. p. 575-600.
3. Sarvanan K, Bapuraj JR, Sharma SC, Radotra BD, Khandelwal N, Suri S. CT and Us evaluation of metastatic cervical lymph nodes with surgicoclinicopathological correlation. *Journal Laryngology Otology* 2002; 116(3):194-9.
4. Rothstein SG, Hornis Kh, Santana Ch. Evaluation of malignant invasion of the carotid artery by CT scan and ultra sound. *Laryngoscope* 1988;98:321-4.
5. Zaragoza L, Sendra F, Solano J, Garido V, Martinez-Morillo M. Ultra-Sonography is more effective than CT in excluding invasion of the carotid wall by cervical lymphadenopathies, *European Journal Radiology* 1993;17(3):91-4.
6. Asai M, Uchida M, Kato T, Zadoni N. CT scan as a diagnostic tool to detect cancer invasion in the carotid artery. *Auris Nasus larynx* 1985;12(suppl2):s98-102.
7. Yoo Gh, Hocwald E, Korkmaz H, Du W, Logani S, Kelly JK, et al. Assessment of carotid artery invasion in patients with head and neck cancer. *Laryngoscope* 2000;110(3pt1):386-90.
8. Wang PZ, Yu Q, Shi HM, Luo JC. Computed tomography diagnosis of maxillofacial and neck malignant tumors invading carotid artery. *Zhonghua Kou Q iang Yixue Za Zhio* 2003;38(5):348-50.
9. Yu Q, Wang P, Shi H, Luo J. Carotid artery and jugular vein invasion of oral-maxillofacial and neck malignant tumors, diagnostic value of CT. *Oral Search Oral Med Pathol Oral Radiol* 2003;96:368-72.