

Sh. Sharif Kashany MD¹
M. Malek MD²
H. Mazaher MD¹
H. Sharifian MD¹

1. Assistant Professor, Department of Radiology, Amir Aalam Hospital, Tehran University of Medical Sciences, Tehran, Iran.

2. Department of Radiology, Amir Aalam Hospital, Tehran University of Medical Sciences, Tehran, Iran.

Corresponding Author:
Shervin Sharif kashany
Address: Amir Aalam Hospital, Sa'adi St., Tehran, Iran.
Tel: +9821-66-70-6106
Fax: +9821-66-70-4805
E-mail: sh_shk_md_rad@yahoo.com

Received August 6, 2007;
Accepted after revision November 10, 2007.

Iran. J. Radiol. 2008;5(1):11-17

The Diagnostic Accuracy of Computed Tomography in Neoplastic Invasion of the Laryngeal Cartilage

Background/Objective: Cartilage invasion is important in the management plan of laryngeal and hypopharyngeal neoplasms. This study was conducted to determine the diagnostic accuracy of computed tomography (CT) to detect the neoplastic invasion of the laryngeal cartilages.

Patients and Methods: 37 patients with proved laryngeal or hypopharyngeal neoplasm that were candidates for total laryngectomy were included in this study. For all patients, standard contrast-enhanced laryngeal CT was performed. Two imaging findings were considered as neoplastic invasion of the laryngeal cartilage—increased density and chondrolysis. These findings were evaluated in thyroid, cricoid and arytenoid cartilages. Then, all patients underwent total laryngectomy and the cartilages were sent for histopathologic evaluation. The sensitivity, specificity, positive predictive value, negative predictive value and positive and negative likelihood ratios of CT findings were evaluated for the diagnosis of neoplastic invasion of these cartilages.

Results: The mean (\pm SD) age of patients was 61.4 ± 8.8 (range: 39–76) years. Thirty-four patients were male; 25 had laryngeal tumor and 12 had hypopharyngeal tumor. Totally, 139 cartilages were evaluated (37 thyroid, 37 cricoid and 65 arytenoid cartilages). Among these cartilages, 49 (16 thyroid, 11 cricoid and 22 arytenoid cartilages) had neoplastic invasion. In thyroid cartilage, the sensitivity of increased density was 0.81 and the specificity of chondrolysis was 0.91; the specificity of both findings together was 0.95. In cricoid cartilage, the sensitivity of increased density was 0.73; the specificity was 0.73; the specificity of chondrolysis was 0.96 and specificity of both findings was 1. In arytenoid cartilage, the specificity of increased density was 0.67; the specificity of chondrolysis was 0.98; and the specificity of both findings together was 1. Considering all 139 cartilages together, the sensitivity of increased density was 0.69 and the specificity of chondrolysis was 0.96. Setting all cartilages in a single group and considering both of these CT findings, the sensitivity was 0.89 and the specificity was 0.76.

Conclusion: Chondrolysis is a specific and increased density is a relatively sensitive CT finding for the diagnosis of laryngeal cartilage neoplastic invasion; considering both findings together makes a very specific imaging finding for the diagnosis.

Keywords: neoplasms, larynx, cartilage, diagnostic tests, tomography, X-ray computed

Introduction

Staging of laryngeal and hypopharyngeal neoplasms is necessary for treatment planning. Laryngeal cartilage invasion alters the neoplasm stage and thus, can affect the management plan (total vs partial laryngectomy).¹⁻³

Neoplastic cartilage invasion reduces response rate to radiotherapy and in comparison to soft tissue involvement, it causes a higher recurrence rate and could also result in post-radiation necrosis.⁴⁻¹⁰

In most cases, neoplastic invasion of the laryngeal cartilage is a contraindication for radiotherapy and speech preserving surgery. As a result, total laryngectomy would be the main choice of treatment, which is a very important factor

influencing patient survival and quality of life.^{3,11-13} Therefore, evaluation of cartilage involvement is essential for clinical staging of laryngeal and hypopharyngeal neoplasms.

Computed tomography (CT) and magnetic resonance imaging (MRI) are applied for evaluation of neoplastic invasion of the laryngeal cartilage.¹² To the best of our knowledge, reports on the accuracy of CT for this purpose is scarce. The objective of this study was to determine the diagnostic accuracy (sensitivity [SE], specificity [SP], negative predictive value [NPV], positive predictive value [PPV], and positive and negative likelihood ratios [PLR and NLR]) of CT in neoplastic invasion of the laryngeal cartilage (thyroid, cricoid and arytenoids) considering the two factors—"increased density" and "chondrolysis," separately and in combination.

Patients and Methods

Patient Selection

In a cross-sectional study from April 2006 to March 2007, we evaluated 37 patients with laryngeal or hypopharyngeal neoplasm. All patients with symptoms suggestive for laryngeal or hypopharyngeal pathology (*i.e.*, hoarseness longer than 14 days and/or dysphagia), who were referred to the Otolaryngology Clinic of Amir Aalam hospital affiliated to Tehran University of Medical Sciences, were candidated for further evaluation by laryngoscopy and/or barium swallow. In the case of hoarseness, the patient underwent laryngoscopy. When the laryngoscopy showed only a nodule confined to true vocal cords, the patient was excluded from the study. If any mass was found in laryngeal—supraglottic and/or glottic—spaces, biopsy was taken. In the case of dysphagia, the patient underwent barium swallow; if a hypopharyngeal mass or any abnormal mucosal irregularity was shown, the patient underwent endoscopy and biopsy. In both above-mentioned situations, if the histopathologic evaluation confirmed squamous cell carcinoma, the patient underwent a standard laryngeal CT with contrast. Considering the findings of laryngoscopy/endoscopy and CT, if the patient fulfilled the criteria for total laryngectomy, (s)he was included in the study. A written informed consent was taken from each patient.

The laryngoscopic indications for total laryngectomy included:

- 1- Anterior commissure involvement,
- 2- Posterior commissure involvement,
- 3- Bilateral true vocal cord involvement (crossing midline),
- 4- Extension of tumor to true vocal cords underneath and subglottic space, and
- 5- All glottic tumors with involvement of false vocal cords and/or aryepiglottic folds,

CT findings indicative for total laryngectomy were:

- 1- Glottic tumor with subglottic and/or supraglottic extension,
- 2- Supraglottic tumors with base of tongue involvement and/or glottic extension,
- 3- Tumors with any extralaryngeal extension (tumor surrounding thyro-hyoid membrane and/or thyroid cartilage), and
- 4- Any laryngeal extension of hypopharyngeal tumor.

Among 67 patients initially eligible for the study, only 37 were enrolled into the study; 28 patients were excluded because the time between CT and surgery was more than two weeks, and 2 patients were also excluded because their histopathologic diagnosis was not squamous cell carcinoma.

Imaging Protocol

All CTs were obtained by a Toshiba scanner (third generation, X-vid, Tokyo, Japan). During imaging, patients were in supine position with hyperextended neck and continuous calm respiration. CT sections performed from the base of tongue to the first tracheal ring, parallel to the true vocal cords.

The slice thickness was 2 mm with an interval of 2 mm. 100 cc Omnipaque 240 (Amersham health cork, Ireland) was administered for all patients as an intravenous bolus. Both soft tissue and bone windows were obtained.

We considered two CT findings as the main signs of neoplastic cartilage invasion: "increased density", and "chondrolysis." Increased density was considered with presence of at least one of the following findings: (Fig. 1)

- 1- Inner and/or outer cartilage cortical thickening with thickness more than 2 mm, and
- 2- Partial or complete increased density of cartilage

medullary cavity (in thyroid and cricoid cartilages) which caused loss of corticomedullary differentiation.

Chondrolysis was considered as the presence of inner cortex erosion or lytic defect and any deeper similar findings (Fig. 2).

All CTs were interpreted by a radiologist experienced in head and neck imaging who was blinded to histopathologic results.

Histopathologic Evaluation

After total laryngectomy, all tissues were sent to the Department of Pathology for histopathologic evaluation of the laryngeal cartilages (*i.e.*, thyroid, cricoid and arytenoids) as the gold standard method for evaluation of cartilage neoplastic involvement. As involvement of hyoid and/or epiglottic cartilages is not determinant for total laryngectomy, we did not perform histopathologic study and CT evaluation for these two cartilages.

In the histopathology, direct invasion of neoplastic cells to perichondrium, collagen bundles and any deeper microscopic invasions were considered neoplastic cartilage invasion, hence, presence of the disease (Figs. 3A and 3B).

Finally, 37 patients were entered to the study. The studied cartilages consisted of 37 thyroid cartilages, 37 cricoid cartilages and 65 arytenoid cartilages. Thereby, a total of 139 cartilages were evaluated.

Statistical Analysis

We calculated the diagnostic indices of CT in the diagnosis of neoplastic invasion of the laryngeal cartilage. These indices were evaluated for "increased density," "chondrolysis" and "both of them together" for each laryngeal cartilage. In our analysis, we considered each arytenoid cartilage as a separate case. Finally, we calculated the above-mentioned diagnostic indices for all 139 cartilages for increased density, chondrolysis and both of these findings. For calculating the diagnostic indices in all cartilages, we used a previously described method.¹⁴ The data were analyzed by STATA (ver. 8/SE).

Results

The mean (\pm SD) age of patients was 61.4 ± 8.8 (range: 39–76) years. Thirty-four patients were male and

Fig. 1. A 62-year-old woman with hoarseness. Laryngeal cartilage neoplastic invasion revealed increased density (white arrow).

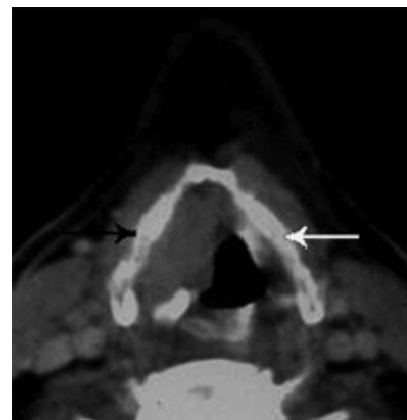
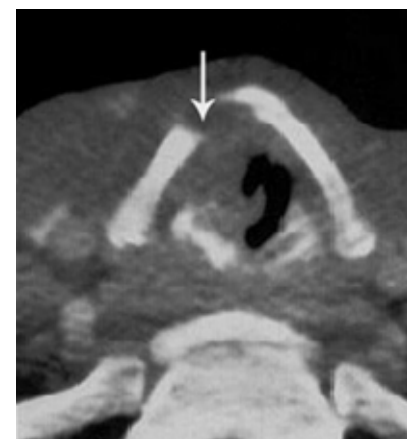
Fig 2. A 57-year-old man with cough. Laryngeal cartilage neoplastic invasion revealed chondrolysis (white arrow).



three were female. Among these 37 patients, 25 had laryngeal tumor—13 had supraglottic, nine had glottic, and three had transglottic tumor. Twelve patients had hypopharyngeal tumor—11 cases originated from the piriform sinus and one originated from the post-cricoid area. As noted earlier, totally 139 cartilages were evaluated: 37 thyroid, 37 cricoid and 65 arytenoid cartilages. Among these cartilages, 49 had neoplastic invasion based on histopathologic findings: 16 thyroid, 11 cricoid and 22 arytenoid cartilages. We calculated the diagnostic indices regarding "increased density," "chondrolysis" and presence of "both these findings together," in CT for the mentioned laryngeal cartilages, separately and in combination.

Thyroid Cartilage

Regarding increased density, the sensitivity was 0.81 and the specificity was 0.38. Regarding chondrolysis these indices were 0.75 and 0.91, respectively. Considering both of these findings together as a marker of neoplastic invasion, the sensitivity was 0.63 and the specificity was 0.95 (Table 1).

Cricoid Cartilage

Regarding increased density, the sensitivity was 0.73 and the specificity was 0.73. Regarding chondrolysis, these indices were 0.36 and 0.96, respectively. Considering both these findings together as a marker of neoplastic invasion, the sensitivity was 0.36 and the specificity was 1 (Table 2).

Arytenoid Cartilage

Regarding increased density, the sensitivity was 0.59 and the specificity was 0.67. Regarding chondrolysis, these indices were 0.46 and 0.98, respectively. Considering both these findings together as a marker of neoplastic invasion, the sensitivity was 0.36 and the specificity was 1 (Table 3).

All Cartilages

Considering all 139 cartilages together, we calculated the diagnostic indices for increased density, chondrolysis and both these findings together. Re-

garding increased density, the sensitivity was 0.69 and the specificity was 0.62. Regarding chondrolysis, these indices were 0.53 and 0.96, respectively. Setting all cartilages in one group and considering both these CT findings for the diagnosis of neoplastic invasion, according to the methods described earlier,¹⁴ the sensitivity was 89 and the specificity was 0.76 (Table 4).

Discussion

Neoplastic invasion of the laryngeal cartilage is a major concern for staging, treatment planning and prognostication of laryngeal and hypopharyngeal neoplasms. In fact, cartilage involvement is one of the determinants which necessitates total laryngectomy.⁸

CT could be used for detecting this involvement and its diagnostic accuracy was evaluated in this study. Some previous studies have focused on this issue and have evaluated the CT accuracy for diagnosis of these

Table 1. Diagnostic Indices of CT for Thyroid Cartilage Neoplastic Invasion

CT Scan Finding	Diagnostic Index				SE [95% CI]	SP [95% CI]	PPV [95% CI]	NPV [95% CI]	PLR [95% CI]	NLR [95% CI]
	Involved		Not Involved							
	TP	FN	TN	FP						
Increased Density	13	3	8	13	0.81 [0.54-0.96]	0.38 [0.18-0.62]	0.5 [0.3-0.7]	0.72 [0.39-0.94]	1.31 [0.87-1.98]	2 [0.64-6.5]
Chondrolysis	12	4	19	2	0.75 [0.48-0.93]	0.91 [0.7-0.94]	0.86 [0.57-0.98]	0.83 [0.61-0.95]	7.9 [2-30.3]	3.6 [1.5-8.6]
Both										
Increased Density and Chondrolysis	10	6	20	1	0.63 [0.35-0.85]	0.95 [0.76-0.99]	0.90 [0.59-0.99]	0.77 [0.56-0.91]	13.1 [1.9-92.3]	2.5 [1.3-4.8]

SE: Sensitivity, SP: Specificity, PPV: Positive Predictive Value, NPV: Negative Predictive Value, PLR: Positive Likelihood Ratio, NLR: Negative Likelihood Ratio

Table 2. Diagnostic Indices of CT for Cricoid Cartilage Neoplastic Invasion

CT Scan Finding	Diagnostic Index				SE [95% CI]	SP [95% CI]	PPV [95% CI]	NPV [95% CI]	PLR [95% CI]	NLR [95% CI]
	Involved		Not Involved							
	TP	FN	TN	FP						
Increased Density	8	3	19	7	0.73 [0.39-0.94]	0.73 [0.52-0.88]	0.53 [0.27-0.79]	0.86 [0.65-0.97]	2.7 [1.3-5.6]	2.7 [1-7.2]
Chondrolysis	4	7	25	1	0.36 [0.1-0.69]	0.96 [0.81-0.99]	0.8 [0.28-0.99]	0.78 [0.6-0.91]	9.5 [1.2-75.3]	1.5 [1-2.4]
Both										
Increased Density and Chondrolysis	4	7	26	0	0.36 [0.11-0.69]	1 [0.87-1]	1 [0.4-1]	0.79 [0.61-0.91]	-----	1.57 [1-2.5]

SE: Sensitivity, SP: Specificity, PPV: Positive Predictive Value, NPV: Negative Predictive Value, PLR: Positive Likelihood Ratio, NLR: Negative Likelihood Ratio

Table 3. Diagnostic Indices of CT for Arytenoid Cartilage Neoplastic Invasion

CT Scan Finding	Diagnostic Index				SE [95% CI]	SP [95% CI]	PPV [95% CI]	NPV [95% CI]	PLR [95% CI]	NLR [95% CI]
	Involved		Not Involved							
	TP	FN	TN	FP						
Increased Density	13	9	29	14	0.59 [0.36-0.79]	0.67 [0.51-0.81]	0.48 [0.29-0.68]	0.76 [0.6-0.89]	1.8 [1-3.2]	1.6 [0.96-2.8]
Chondrolysis	10	12	42	1	0.46 [0.24-0.68]	0.98 [0.88-0.99]	0.90 [0.59-0.99]	0.78 [0.64-0.88]	19.5 [2.7-143]	1.8 [1.2-2.6]
Both Increased Density and Chondrolysis	8	14	43	0	0.36 [0.17-0.59]	1 [0.92-1]	1 [0.63-1]	0.75 [0.62-0.86]	-----	1.6 [1.1-2.2]

SE: Sensitivity, SP: Specificity, PPV: Positive Predictive Value, NPV: Negative Predictive Value, PLR: Positive Likelihood Ratio, NLR: Negative Likelihood Ratio

Table 4. Diagnostic Indices of CT for All Cartilages Neoplastic Invasion

CT Scan finding	SE	SP	PPV	NPV
Increased Density	0.69	0.62	0.50	0.79
Chondrolysis	0.53	0.96	0.87	0.79
Both Increased Density and Chondrolysis	0.89	0.76	0.68	0.91

SE: Sensitivity, SP: Specificity, PPV: Positive Predictive Value, NPV: Negative Predictive Value

cartilages neoplastic involvements.^{1,4,12,15-18}

Laryngeal cartilages are seen in two different histologic patterns—nonossified and ossified. Therefore, in evaluation of laryngeal cartilages in CT, we should consider two different patterns of nonossified hyaline cartilage and ossified cartilage with cortex and fatty medullary cavity. This fact causes different attenuation values of laryngeal cartilages in CT. The neoplastic cartilage invasion could result in pathologic ossification of the cartilage. This should not be mistaken with the physiologic ossification process.⁴ Neoplastic increased density and sclerosis could be mistaken with the physiologic ossification in CT; both of them

are seen as increased density. Presence of cortex and fatty medullary cavity implies physiologic ossification process, whereas increased density seen in the forms of cartilage cortex thickening and/or partial or complete loss of cortico-medullary differentiation (due to medullary cavity hyperdensities) could imply a pathologic process.⁴ However, physiologic ossification of most arytenoid and some thyroid cartilages could present as homogenous increased density without any corticomedullary differentiation and/or increased cortical thickness;¹⁹ mistaking these cases as neoplastic laryngeal invasion could result in increased rate of false positive, which in turn reduces the specificity

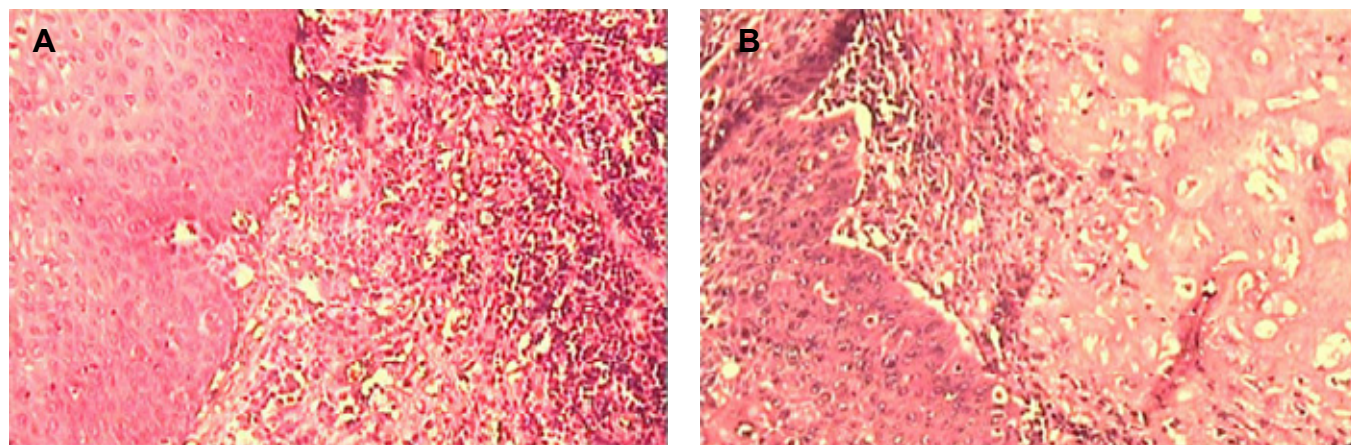


Fig. 3. Histopathologic feature of cartilage invasion: A- involvement of perichondral tissues (this involvement would present as an increased density region in CT); B- involvement of the cartilage matrix. This involvement would present as chondrolysis in CT.

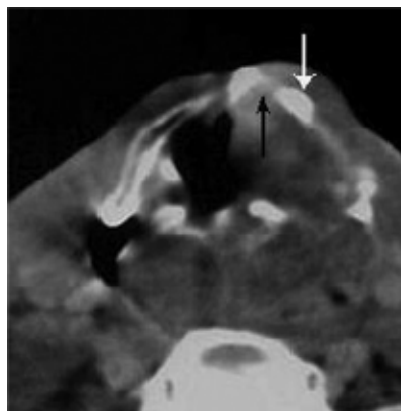


Fig. 4. A 45-year-old man with hoarseness. Both increased density (white arrow) and chondrolysis (black arrow) present in his thyroid cartilage.

and positive predictive value of this finding, as it has been seen in our study. Considering these points, the presence of increased density and sclerosis would be a relatively sensitive CT finding of neoplastic cartilage invasion, as was observed in this study (sensitivities of 0.59–0.81). Similar results have been reported in other studies.⁴ In our study, comparing the sensitivities of increased density and sclerosis among three laryngeal cartilages, we could see the highest value in the thyroid cartilage. Most of the laryngeal neoplasms originate from true vocal cords (especially, in anterior one-third of the cords) which are adjacent to thyroid cartilage. This fact could make the direct invasions of neoplasms to thyroid cartilage more frequently than is seen as increased density. Furthermore, this close relation could result in neoplastic irritation and thus thyroid cartilage reaction which could be resulted in higher sensitivity.⁴

Considering the greater importance of reducing unnecessary total laryngectomies in these patients, we should choose the more specific CT finding. According to the above-mentioned facts about mistaking physiologic increased density with neoplastic cartilage increased density and sclerosis, we can predict lower specificity for this finding as was shown in our study (specificities of 0.38–0.73). Therefore, the increased density would not be a suitable and specific indication for total laryngectomy.

The ability of CT for detection of neoplastic laryngeal cartilage invasion varies widely with reported sensitivities of 0.46–0.91 and specificities of 0.68–0.94. These variations in some part are due to different CT techniques used (*e.g.*, applying scan times of 4–9 s/slice and slice thickness of 4–6 mm in earlier studies). Another important reason is considering variable diagnostic criteria for neoplastic invasion of the

laryngeal cartilage.⁴ For example, Becker, *et al*, in a paper published in 1995 considered the following findings as neoplastic cartilage invasion in CT: Presence of neoplasm on the inner and outer aspects of cartilage; and asymmetric sclerosis of cricoid and arytenoid cartilages.¹

Regarding chondrolysis and erosion, we obtained the high specificities of 0.91–0.98 in different laryngeal cartilages. This means that erosion is a specific CT finding for diagnosis of neoplastic cartilage invasion, which could be due to the fact that erosion in the majority of cases develops in response to direct neoplastic involvement in contrary to some nonspecific findings such as increased density which could also happen in response to inflammatory reactions in addition to neoplastic involvement. This finding is similar to other reports which have shown specificities of 0.86–1 in detection of thyroid, cricoid and arytenoid neoplastic invasion.^{1,4,16,20} The higher specificities of cartilage erosion in CT could mean the higher positive predictive value of this finding and makes it a suitable indicator for management and treatment planning. However, we should keep in mind that the sensitivity of this finding, as we observed in our study, may be low (0.36–0.75). Thyroid cartilage can be physiologically ossified in an irregular pattern in comparison to arytenoid cartilages. This physiologic ossification may be mistaken with lysis due to neoplastic invasion. Therefore, the specificity of the erosion in CT is higher for neoplastic invasion of the arytenoid.¹⁵ Otherwise, this finding has an acceptable specificity for detection of neoplastic cartilage invasion.

As previously noted, CT findings for neoplastic invasion of the laryngeal cartilage are variable. These include increased density and sclerosis, obliteration of cartilage medullary cavity, serpiginous contour, bowing, cartilage blow out, cartilage erosion and chondrolysis, presence of tumor adjacent to nonossified cartilage and extralaryngeal tumor.^{1,4} These different findings have shown variable sensitivity and specificity. As an example, in a study that has separately considered the extralaryngeal tumor, sclerosis, tumor adjacent to nonossified cartilage, serpiginous contour, erosion or lysis and obliteration of the cartilage medullary space for neoplastic invasion of the laryngeal cartilage, the sensitivities of three laryngeal

cartilages have varied from 0.32–0.83 and the specificities have varied from 0.4–1. The highest sensitivity was for sclerosis in the thyroid and cricoid cartilages and the lowest sensitivity was for arytenoid cartilage medullary space obliteration. The highest specificity was for cricoid cartilage erosion and the lowest was for thyroid cartilage sclerosis.⁴ For this reason, we selected only sclerosis and chondrolysis for evaluation of neoplastic invasion of the laryngeal cartilage in the current study.

Overall, it seems that as individual CT findings, the increased density and sclerosis are the most sensitive determinants, while the erosion and chondrolysis are the most specific CT findings for the diagnosis of neoplastic invasion of the laryngeal cartilage. For better detection of neoplastic invasion of the laryngeal cartilage, we combined the two mentioned findings (*i.e.*, both “increased density” and “chondrolysis”) as indicator of cartilage invasion (Fig. 4). By doing so, we came into higher specificities but lower sensitivities for detection of all three cartilages neoplastic invasion (specificities of 0.95–1 for individual cartilages) (Tables 1-3). Especially, the specificity of this combination for cricoid and arytenoid was 1; this means that if we could show both these findings in the cricoid or arytenoid cartilage, we can consider cartilage neoplastic invasion.

References

1. Becker M, Zbären P, Delavelle J, Kurt AM, Egger C, Rufenacht DA, et al. Neoplastic invasion of the laryngeal cartilage: reassessment of criteria for diagnosis at CT. *Radiology* 1997 May;203(2):521-32.
2. Castelijns JA, van den Brekel MW, Tobi H, Smit EM, Golding RP, van Schaik C, et al. Laryngeal carcinoma after radiation therapy: correlation of abnormal MR imaging signal patterns in laryngeal cartilage with the risk of recurrence. *Radiology* 1996;198(1):151-5.
3. Castelijns JA, Becker M, Hermans R. Impact of cartilage invasion on treatment and prognosis of laryngeal cancer. *Eur Radiol* 1996;6(2):156-69.
4. Becker M. Neoplastic invasion of laryngeal cartilage: radiologic diagnosis and therapeutic implications. *Eur J Radiol* 2000 Mar;33(3):216-29.
5. Becker M, Schroth G, Zbären P, Delavelle J, Greiner R, Vock P, et al. Long-term changes induced by high-dose irradiation of the head and neck region: imaging findings. *Radiographics* 1997 Jan-Feb;17(1):5-26.
6. Curtin HD. Imaging of the larynx: Current concepts. *Radiology* 1989 Oct;173(1):1-11.
7. Curtin HD. The larynx. In: Som PM, Curtin HD, editor. *Head and Neck Imaging*. 3th ed., St Louis: Mosby-Year Book; 1996. p. 612-707.
8. Curtin HD. The importance of imaging demonstration of neoplastic invasion of laryngeal cartilage. *Radiology* 1995 Mar;194(3):643-4.
9. Million RR. The myth regarding bone or cartilage involvement by cancer and the likelihood of cure by radiotherapy. *Head Neck* 1989 Jan-Feb;11(1):30-40.
10. Wolf G, Hong K, Fisher S. Induction chemotherapy plus radiation compared with surgery plus radiation in patients with advanced laryngeal cancer. *N Engl J Med* 1991 Jun 13;324(24):1685-90.
11. Thoeny HC, Delaere PR, Hermans R. Correlation of local outcome after partial laryngectomy with cartilage abnormalities on CT. *AJNR Am J Neuroradiol* 2005 Mar;26(3):674-8.
12. Becker M, Zbären P, Laeng H, Stoupis C, Porcellini B, Vock P. Neoplastic invasion of the laryngeal cartilage: comparison of MR imaging and CT with histopathologic correlation. *Radiology* 1995 Mar;194(3):661-9.
13. Tart RP, Mukherji SK, Lee WR, Mancuso AA. Value of laryngeal cartilage sclerosis as a predictor of outcome in patients with stage T3 glottic cancer treated with radiation therapy. *Radiology* 1994;192:567-570.
14. Drake C, Levine RA. Sensitivity, specificity and other diagnostic measures with multiple sites per unit. *Contemp Clin Trials*. 2005 Apr;26(2):252-9.
15. Zbären P, Becker M, Läng H. Pretherapeutic staging of laryngeal carcinoma: clinical findings, computed tomography, and magnetic resonance imaging compared with histopathology. *Cancer* 1996 Apr 1;77(7):1263-73.
16. Castelijns JA, Gerritsen GJ, Kaiser MC, Valk J, van Zanten TE, Golding RG, et al. Invasion of laryngeal cartilage by cancer: comparison of CT and MR imaging. *Radiology* 1988;167(1):199-206.
17. Munoz A, Ramos A, Ferrando J, Gomez B, Escudero L, Relea F, et al. Laryngeal carcinoma: sclerotic appearance of the cricoid and arytenoid cartilage-CT-pathologic correlation. *Radiology* 1993;189(2):433-7.
18. Amilibia E, Juan A, Nagues J, Manos M, Monfort JL, Dicenta M. Neoplastic invasion of laryngeal cartilage: diagnosis by computed tomography. *Acta Otorrinolaringol Esp* 2001;52(3):207-10.
19. Schmalfuss IM, Mancuso AA, Tart RP. Arytenoid cartilage sclerosis: normal variations and clinical significance. *AJNR Am J Neuroradiol* 1998;19(4):719-22.
20. Sulfaro S, Barzan L, Querin F, Lutman M, Caruso G, Comoretto R, et al. Staging of the laryngohypopharyngeal carcinoma. A 7-year multidisciplinary experience. *Arch Otolaryngol Head Neck Surg* 1989 May;115(5):613-20.