

ISSN: Print 1735-1065, Online: 2008-2711

# IRANIAN JOURNAL OF RADIOLOGY

Official Quarterly Journal of Iranian Society of Radiology

Number 35, Volume 9, Issue 3, September 2012



Iranian Society of  
Radiology



Tehran University of  
Medical Sciences

[www.IranJRadiol.com](http://www.IranJRadiol.com)

### Original Articles

- 111 Prevalence of Congenital Coronary Artery Anomalies and Variants in 2697 Consecutive Patients Using 64-Detector Row Coronary CT-Angiography**  
*Abbas Arjmand Shabestari, Shahram Akhlaghpour, Reza Tayebivaljozi, Farzaneh Fattahi Masrour*
- 122 Space Occupying Lesions in the Fetal Chest Evaluated by MRI**  
*Umit Aksoy Ozcan, Ersan Altun, Latif Abbasoglu*
- 130 Developing Criteria for Lumbar Spine Magnetic Resonance Imaging (MRI) Using RAND Appropriateness Method (RAM)**  
*Ali Keshtkaran, Mohammad Hadi Bagheri, Rahim Ostovar, Hedayat Salari, Majid Reza Farokhi, Atefeh Esfandiari, Hossein Yousefimanesh*
- 139 Diagnostic Accuracy of Transvaginal Sonography in the Detection of Uterine Abnormalities in Infertile Women**  
*Maryam Niknejadi, Hadieh Haghghi, Firoozeh Ahmadi, Fatemeh Niknejad, Mohammad Chehrizi, Ahmad Vosough, Deena Moenian*
- 145 Radiation Dose to Newborns in Neonatal Intensive Care Units**  
*Mohammad Taghi Bahreyni Toossi, Malakeh Malekzadeh*

### Case Reports

- 150 The Value of Changing Position in the Detection of CSF Leakage in Spontaneous Intracranial Hypotension Using Tc-99m DTPA Scintigraphy: Two Case Reports**  
*Yu-Yu Lu, Hsin-Yi Wang, Ying Lin, Wan-Yu Lin*
- 154 Effect of Hypertransfusion on Extramedullary Hematopoietic Compression Mass in Thalassemia Major: A Case Report**  
*Mohammadreza Emamhadi, Ahmad Alizadeh*
- 157 Skull Base Aneurysmal Bone Cyst Presented with Foramen Jugular Syndrome and Multi-Osseous Involvement**  
*Leila Aghaghazvini, Nahid Sedighi, Parisa Karami, Omid Yeganeh*
- 161 Solitary Metastasis of Gastric Cancer to Fibula: A Case Report**  
*Sepideh Hekmat, Tahereh Ghaedian, Hossein Barati, Mansour Movahed*

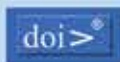

### Letter to Editor

- 165 A Primary Giant Hydatid Cyst of the Ovary**  
*Abdurrahman Kaya, Sibel Yildiz, Reşat Özaras, Ali Mert*

# IRANIAN JOURNAL OF RADIOLOGY



Kowsar accepts terms & conditions of



**CROSS**



**OPEN ACCESS**



Address: Iranian Journal of Radiology Office, Medical Imaging Center, Imam Khomeini Hospital, Keshavarz Blvd., Tehran, Iran.

Tel: +98 21 66581579 +98 21 66944041 Fax: +98 21 66581578 Email: info@iranjradiol.com

## Indexing Sources

**International:** Science Citation Index Expanded (SCIE), Web of Knowledge, Thomson Reuters (ISI), SCOPUS, EMBASE, CABI, EBSCO, Index Medicus for the WHO Eastern Mediterranean Region (IMEMR), Index Copernicus

**Local:** ISC, SID (Scientific Information Database), Iran Medex