

ISSN: Print 1735-1065, Online: 2008-2711

IRANIAN JOURNAL OF RADIOLOGY

Official Quarterly Journal of Iranian Society of Radiology

Number 33, Volume 9, Issue 1, March 2012



Iranian Society of
Radiology



Tehran University of
Medical Sciences

www.IranJRadiol.com

Original Articles

- 1 **Value of Proton-MR-Spectroscopy in the Diagnosis of Temporal Lobe Epilepsy; Correlation of Metabolite Alterations With Electroencephalography**
Hasan Aydin, Nilay Aydin Oktay, Volkan Kizilgoz, Elif Altin, Idil Gunes Tatar, Baki Hekimoglu
- 12 **Color Doppler Indices of Orbital Arterial Flow in End-Stage Renal Disease Patients; Are the Changes Related to Chronic Hemodialysis or Chronic Renal Failure?**
Hadi Rokni Yazdi, Safoura Faraji, Farokhlegha Ahmadi, Reza Shahmirzae
- 17 **Diagnostic Accuracy of Digital and Conventional Radiography in the Detection of Non-Cavitated Approximal Dental Caries**
Farida Abesi, Alireza Mirshekar, Ehsan Moudi, Maryam Seyedmajidi, Sina Haghanifar, Nima Haghighat, Ali Bijani
- 22 **Detection and Severity Scoring of Chronic Obstructive Pulmonary Disease Using Volumetric Analysis of Lung CT Images**
Mohammad Parsa Hosseini, Hamid Soltanian-Zadeh, Shahram Akhlaghpour

Case Reports

- 28 **The Role of Multidetector CT in the Diagnosis of Retroperitoneal Fibrosis: Report of a Case**
Hossein Ghanaati, Mehdi Mohammadifar, Mahsa Ghajarzadeh, Kavous Firouznia, Marzieh Motevalli, Amir Hossein Jalali
- 32 **Desmoid Tumor Associated With Familial Adenomatous Polyposis: Evaluation With 64-Detector CT Enterography**
Oktay Algin, Sehnaz Evrimler, Evrim Ozmen, Melike Metin, Osman Ersoy, Mustafa Karaoglanoglu
- 37 **Necrotizing Sarcoid Granulomatosis Mimicking Lung Malignancy: MDCT, PET-CT and Pathologic Findings**
Hilal Sahin, Naim Ceylan, Selen Bayraktaroglu, Sezai Tasbakan, Ali Veral, Recep Savas
- 42 **Hypothalamic Cavernous Angioma Associated With Memory and Behavior Disturbance Attacks: Role of Imaging in Diagnosis**
Preetam Bhujagonda Patil, Muralidhar Gururajrao Kamalapur, Jayaraj Chandrashekhara Sindhur, Shyamsundar Krishnabhat Joshi
- 45 **Intraosseous Neurofibroma and Concurrent Involvement of the Mandible, Maxilla and Orbit: Report of a Case**
Zahra Dalili, Gholamhossein Adham

CONTENTS

Pictorial Essay

50 Bony Lesions in Pediatric Acute Leukemia: Pictorial Essay

Makhtoom Shahnazi, Alireza Khatami, Bibishahin Shamsian, Bibimaryam Haerizadeh, Mastooreh Mehrafarin

Letters to Editor

57 A Case of Chondrosarcoma That Primarily Developed in the Cervical Spine

Ali Hekmatnia, Amirhossein Ghazavi, Bahram Aminmansour, Parvin Mahzouni

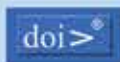

60 Evaluation of Radiographic Pattern of Male Urethral Strictures in Nigeria: A Preliminary Report of a Proposed New Scoring System for Developing Countries

Ahmed Ahidjo, Adekunle Yishau Abdulkadir, Ibrahim Ahmed Gadams, Suleiman Tanimu Saad

IRANIAN JOURNAL OF RADIOLOGY



Kowsar accepts terms & conditions of



cross



COMMITTEE ON PUBLICATION ETHICS



OPEN ACCESS



Address: Iranian Journal of Radiology Office, Medical Imaging Center, Imam Khomeini Hospital, Keshavarz Blvd., Tehran, Iran.

Tel: +98 21 66581579 +98 21 66944041 Fax: +98 21 66581578 Email: info@iranjradiol.com

Indexing Sources

International: Science Citation Index Expanded (SCIE), Web of Knowledge, Thomson Reuters (ISI), SCOPUS, EMBASE, CABI, EBSCO, Index Medicus for the WHO Eastern Mediterranean Region (IMEMR), Index Copernicus

Local: ISC, SID (Scientific Information Database), Iran Medex