

ISSN: Print 1735-1065, Online: 2008-2711

# IRANIAN JOURNAL OF RADIOLOGY

Official Quarterly Journal of Iranian Society of Radiology

Number 34, Volume 9, Issue 2, June 2012



Iranian Society of  
Radiology



Tehran University of  
Medical Sciences

[www.IranJRadiol.com](http://www.IranJRadiol.com)

### Original Articles

- 63 Comparison of Allergic Adverse Effects and Contrast Enhancement Between Iodixanol and Iopromide**  
*Farideh Gharekhanloo, Saadat Torabian*
- 67 Decrease in Infection Rate Following Use of Povidone-Iodine During Transrectal Ultrasound Guided Biopsy of the Prostate: A Double Blind Randomized Clinical Trial**  
*Mahyar Ghafoori, Madjid Shakiba, Hamidreza Seifmanesh, Kamal Hoseini*
- 71 Morphometric Analysis of the Internal Auditory Canal by Computed Tomography Imaging**  
*Sergio Ricardo Marques, Sergio Ajzen, Giuseppe D' Ippolito, Luis Alonso, Sadao Isotani, Henrique Lederman*
- 79 Ultrasonic Measurement of Common Carotid Intima-Media Thickness in Type 2 Diabetic and Non-Diabetic Patients**  
*Ahmad Alizadeh, Ali Roudbari, Abtin Heidarzadeh, Ali Babaei Jandaghi, Maryam Bani Jamali*
- 83 Determination of Vertical Interproximal Bone Loss Topography: Correlation Between Indirect Digital Radiographic Measurement and Clinical Measurement**  
*Farzad Esmaeli, Adileh Shirmohammadi, Masoumeh Faramarzie, Nader Abolfazli, Hossein Rasouli, Saied Fallahi*

### Case Reports

- 88 Primary Diffuse Large B Cell Lymphoma of the Cranial Vault**  
*Kiara Rezaei-Kalantari, Kaveh Samimi, Maryam Jafari, Mohammad Ali Karimi, Keyvan Ansari, Mohammad Davoodi, Mahtab Nabi-Meybodi, Mehrnoush Gorjian*
- 93 An Unusual Case of Pulmonary Adenocarcinoma with Multiple and Extraordinary Metastases**  
*Hamid Reza Haghghatkhah, Morteza Sanei Taheri, Seyed Mohammad Hadi Kharrazi, Damoon Ghazanfari Amlashi, Mehrnoosh Haddadi, Mahin Pourabdollah*
- 99 Congenital Pseudohorseshoe Lung Associated with Scimitar Syndrome**  
*Alptekin Tosun, Serife Leblebisatan*
- 103 Occipital Artery Arising from the Anterior Aspect of the Internal Carotid Artery Identified by Three-Dimensional Computed Tomography Angiography**  
*Toshinori Iwai, Toshiharu Izumi, Tomio Inoue, Jiro Maegawa, Nobukazu Fuwa, Kenji Mitsudo, Iwai Tohnai*

# CONTENTS

## **Photo Quiz**

### **106 What is Your Diagnosis?**

*Abbas Khodayari Namin, Sanam Mirbaigi, Fereshteh Ensani*

## **Letter to Editor**

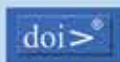

### **109 Tonsilolith in Routine Panoramic Radiographies; Is It a Common Incidental Finding?**

*Mohammad Mehdi Aghdasi, Solmaz Valizadeh, Niloofar Amin-Tavakoli, Hooman Bakhshandeh*

# IRANIAN JOURNAL OF RADIOLOGY



Kowsar accepts terms & conditions of



Address: Iranian Journal of Radiology Office, Medical Imaging Center, Imam Khomeini Hospital, Keshavarz Blvd., Tehran, Iran.

Tel: +98 21 66581579 +98 21 66944041 Fax: +98 21 66581578 Email: info@iranjradiol.com

## Indexing Sources

**International:** Science Citation Index Expanded (SCIE), Web of Knowledge, Thomson Reuters (ISI), SCOPUS, EMBASE, CABI, EBSCO, Index Medicus for the WHO Eastern Mediterranean Region (IMEMR), Index Copernicus

**Local:** ISC, SID (Scientific Information Database), Iran Medex